

Graves' disease with unilateral radioisotope uptake

We present the case of a young caucasian woman with hyperthyroidism and hepatitis C virus infection (HCV). The reason for hyperthyroidism was Graves' disease, an autoimmune disorder of the thyroid gland leading to excessive thyroid hormone biosynthesis and release. The patient suffered from typical symptoms of hyperthyroidism. Ophthalmopathy, one of the typical symptoms for Graves' disease clinically occurs in 41% of the patients with Graves' disease when thyreotoxicosis is diagnosed. However, it was not present. Usually, both thyroid lobe involvement and ophthalmopathy occur bilaterally. Scintigraphy of the thyroid gland normally reveals a bilateral, homogenously increased uptake of the radioisotope (e. g. $^{99m}\text{TcO}_4^-$) in both thyroid lobes. In the literature, there is only one publication of Graves' disease with unilateral involvement of the thyroid gland. There are a few other cases with unilateral goiter and Graves' disease, but in these patients the unilateral scintigraphic uptake was due to aplasia of either the right or left lobe of the thyroid gland.

Case report

The woman (age: 33 years) presented with clinical and laboratory findings of hyperthyroidism, such as fatigue, heat intolerance, sweating, and weight loss. Additionally, the patient suffered from chronic hepatitis C. She was treated with PEGylated interferon. Ribavirin had to be discontinued due to active autoimmune thyroid disease. The clinical examination revealed a slightly enlarged, asymmetric goiter with a prominent right lobe. On the left side, regular thyroid tissue was palpable. The thyroid on both sides was indolent, moved with swallowing, and was not fixed to the overlying tissues. The patient neither presented signs of an exophthalmus nor pretibial myxoedema.

High-resolution sonography (Combison 310 A⁺, Kretztechnik AG, Austria), using a 7.5 MHz mechanical sector probe coupled with a silicone rubber kit) of the gland revealed an enlarged right lobe with in-

creased, inhomogenous echo and unclear boundaries to the adjacent soft tissue. No evidence for nodular alterations was found. In contrast, the left lobe was of normal size and had uniform echo throughout the entire lobe (Fig. 1).

The scintigraphy of the thyroid (37 MBq $^{99m}\text{TcO}_4^-$) was performed utilizing a gamma camera (Siemens GAMMASONICS-ZLC, Des Plaines, Illinois, USA) showing a two-fold increase of $^{99m}\text{TcO}_4^-$ uptake in the

enlarged right lobe, whereas the left lobe showed a suppressed uptake in a regularly sized lobe (Fig. 2).

Concentrations in the serum of free thyroxin (fT4) (measured by a competitive chemoluminescent immunoassay; Bayer Diagnostics., Fernwald-Gießen) was 36 pmol/l (reference range: 10-22 pmol/l), free triiodine (fT3) (measured by a competitive chemoluminescent immunoassay; Bayer Diagnostics., Fernwald-Gießen) 11 pmol/l (reference range: 3.1-6.5 pmol/l), thyroid stimulating hormone (TSH) (determined by a two-site chemoluminometric

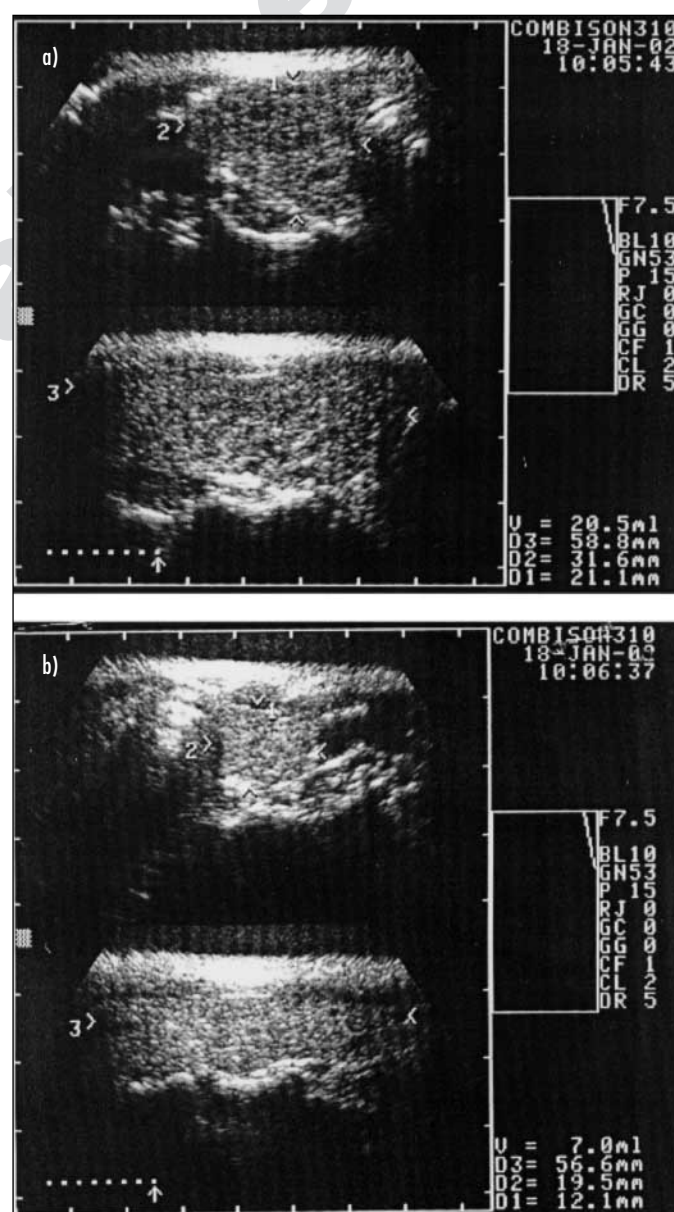


Fig. 1 High resolution sonography of the thyroid gland. The right lobe (a) is enlarged (5.8 x 3.1 x 2.1 cm) with boundaries hardly to delineate and with increased echos distributed throughout the lobe. The left lobe (b) is normal sized (5.6 x 1.9 x 1.2 cm), showing well defined boundaries and regular echos throughout the lobe.

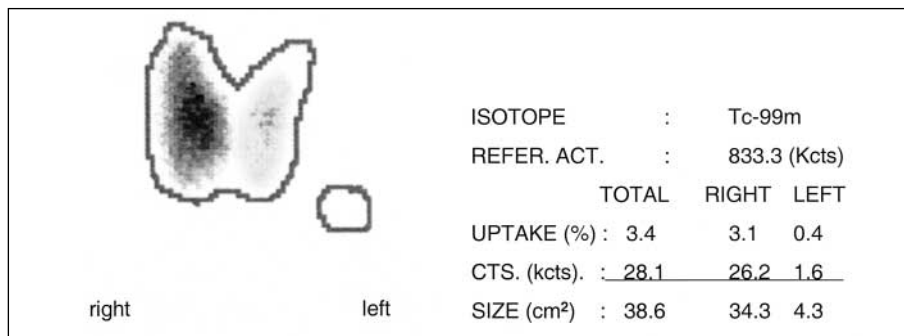


Fig. 2 $^{99m}\text{TcO}_4$ scan of the thyroid gland: homogenously distributed $^{99m}\text{TcO}_4$ uptake twofold increased in the right lobe and suppressed in the left lobe as compared to normal uptake

immunoassay; Bayer Diagnostics., Fernwald-Gießen) <0.01 mU/l (reference range: 0.35-4.5 mU/l). Activity of serum antibodies to TSH-receptor (TRAb, measured by RIA; Brahms, Berlin) was 9.2 U/l (reference range: <1.5 U/l), to thyroid peroxidase (TPOAb, measured by RIA; Bayer Diagnostics., Fernwald-Gießen) 3460 U/ml (reference range: <60 U/ml), to thyroglobulin (TGAb, measured by RIA; Bayer Diagnostics., Fernwald-Gießen) 1070 U/ml (reference range: <40 U/ml).

Fine needle aspiration (FNA) was performed on the right and left lobe of the thyroid gland (Microlance, 20 G 1,5 “, 0.9×4.0) in multiple sites; 5 smears for each lobe were evaluated. Cytology specimens obtained from the right lobe were cellular, disclosing densely packed lymphocytes, few follicular center cells and histiocytes. Follicular cells were scant mostly showing oncocyctic changes. Multinucleated

giant cells and colloid were not present. These cytologic findings are compatible with focal lymphocytic thyroiditis occurring in the context of Graves' disease (4). In contrast, FNA specimens of the left lobe showed few isolated normal appearing follicular cells (Fig. 3).

Consideration of the signs and symptoms, as well as laboratory findings and imaging led to the diagnosis of a hyperthyroidism of Graves' disease involving only the right lobe of the thyroid gland. The patient obtained 40 mg thiamazol daily. A complete relief in symptoms of hyperthyroidism was noticed after four weeks. At this time, serum concentration of fT4 and fT3 had normalized, whereas TSH values remained suppressed. For this reason, therapy with thiamazol was reduced to 20 mg/d. After four months of therapy, TSH value was within the reference range, while values for fT3 and fT4 were in the lower

reference range. After six months of therapy a block and replace course of treatment was started with 5 mg/d thiamazol and 50 $\mu\text{g/d}$ levothyroxin. At this time, serum concentrations of all thyroid hormone parameters were within the reference ranges. HR-ultrasonography revealed minimal residual changes in the right lobe. The left lobe remained of normal size and structure. Scintigraphy after six months of therapy still showed an increased $^{99m}\text{TcO}_4$ uptake in the enlarged right lobe as compared to the left one. Serum concentration of TRAb amounted to 4.3 U/l, those of TPOAb and TGAb had decreased significantly to upper reference ranges as compared to the values at baseline.

Discussion

After Dimai et al. (3), we report for the second time of a patient presenting with hyperthyroidism due to Graves' disease with unilateral involvement of a bilobed thyroid gland. Other cases with hyperthyroidism and involvement of one thyroid lobe were published, but in all of them hyperthyroidism started after previous hemithyroidectomy due to goiter. Analysis obtained from an extended review of the literature revealed, that the main risk factors for Graves' disease are multifactorial. However, iodide deficiency and modulation of the autoimmune response by oestrogen seem to be predominant. Autoimmune thyroid diseases such as Graves' disease and Hashimoto thyroiditis share many immunological features. These include a lymphocytic infiltrate of the thyroid, as demonstrated in the present case by FNA cytology (4), and autoreactivity against the key thyroid autoantigens, thyroglobulin, thyroid peroxidase and the thyroid stimulating hormone receptors (TSH-R) (1). Autoantibodies directed against TSH-R affect the activity of thyroid cells either by binding to the TSH-R, activating adenylate cyclase resulting in an increase in cyclic adenosine-3'5'-monophosphate TSH receptor binding stimulating antibodies (TSAb), or by binding to the receptor and blocking the availability to TSH receptor blocking antibodies (TBAbs) (5). Iodine transport is mediated by a specific sodium-

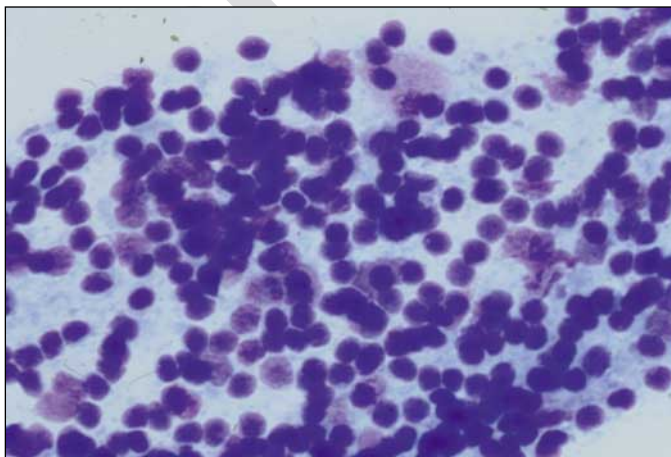


Fig. 3 Fine needle aspiration specimens from the right lobe (stained according to May-Grunwald-Giemsa): cellular, disclosing densely packed lymphocytes, few follicular center cells and histiocytes

dependent iodide transporter (NIS) located at the basolateral membrane of thyroid follicular cells (2). NIS cotransports two sodium ions along with one iodide ion, with the transmembrane sodium gradient serving as the driving force for iodide uptake. With immunohistochemistry using monoclonal and polyclonal anti-hNIS-antibodies, Graves' thyroid disease reveals abundant NIS immunoreactivity at the basolateral aspect of most thyroid follicular cells, which is consistent with the clinical observation of diffusely increased radioiodine (and thus of $^{99m}\text{TcO}_4^-$) uptake in active Graves' thyrotoxicosis.

Thus, it might be speculated that interaction of only one lobe with these antibodies might be caused by side-to-side differences of multifactorial origin. One reason might be, that suppression of NIS gene expression and function may be caused by cytokines (TNF- α , IFN- α , IL-1 α were shown to inhibit NIS mRNA and IL-1 α , IL-6 decreased NIS RNA expression in thyroid cells) which may be responsible, at least in part, for development of impaired radioiodine uptake by

thyroid tissue as it was published for Hashimoto thyroiditis, especially during early stages of hyperthyroidism. Another reason might be the isolated lymphatic draining of each lobe, which may lead to different auto-reactivity against the key thyroid auto-antigens and the thyroid stimulating hormone receptors (TSH-R) (1). This in part would also support the hypothesis of Dimai et al. (3), who postulated that the side-to-side difference may be caused by bacterial or viral infection of the thyroid gland. In fact, most thyroid infections are due to lymphatic seeding and may lead to inhomogenous alteration of thyroid tissue.

Conclusion

This is the second report describing a very rare case of hyperthyroid Graves' disease with unilateral involvement of the thyroid gland. The aetiology of this unilateral involvement remains unclear, even if reasons leading to inhomogenous local antigen expression seem to be predominant and further investigations should be performed.

References

1. Dayan CM, Daniels GH. Chronic autoimmune thyroiditis. *N Engl J Med* 1996; 335: 99-107.
2. De La Vieja A, Dohan O, Levy O et al. Molecular analysis of the sodium/iodide symporter: impact on thyroid and extrathyroid pathophysiology. *Physiol Rev* 2000; 80: 1083-105.
3. Dimai HP, Ramschak-Schwarzer S, Lax S et al. Hyperthyroidism of Graves' disease: evidence for only unilateral involvement of the thyroid gland in a 31-year-old female patient. *J Endocrinol Invest* 1999; 22: 215-9.
4. Droese M. Fine needle puncture of the thyroid gland: technic and diagnostic possibilities. *Internist* 1983; 24: 467-73.
5. Rapoport B, Chazenbalk GD, Jaume JC et al. The thyrotropin (TSH) receptor: interaction with TSH and autoantibodies. *Endocr Rev* 1998; 19: 673-716.

Eingegangen: 20. November 2003; in revidierter Form: 16. März 2004

S. Gratz¹, P. Barth², R. Arnold³, TM. Behr¹
 Department of ¹Nuclear Medicine, ²Pathology, ³Internal Medicine,
 Division of Gastroenterology, Endocrinology and Metabolism,
 Philipps-University of Marburg, Germany